

Anatomic Problems of the Colon

National Digestive Diseases Information Clearinghouse



National
Institute of
Diabetes and
Digestive
and Kidney
Diseases

NATIONAL
INSTITUTES
OF HEALTH

The colon, or large intestine, is part of the digestive system, which is a series of organs from the mouth to the anus. When the shape of the colon or the way it connects to other organs is abnormal, digestive problems result. Some of these anatomic problems can occur during embryonic development of the fetus in the womb and are known as congenital abnormalities. Other problems develop with age.

Knowing how the colon develops and how it works provides a basis for understanding the specific anatomic problems that follow:

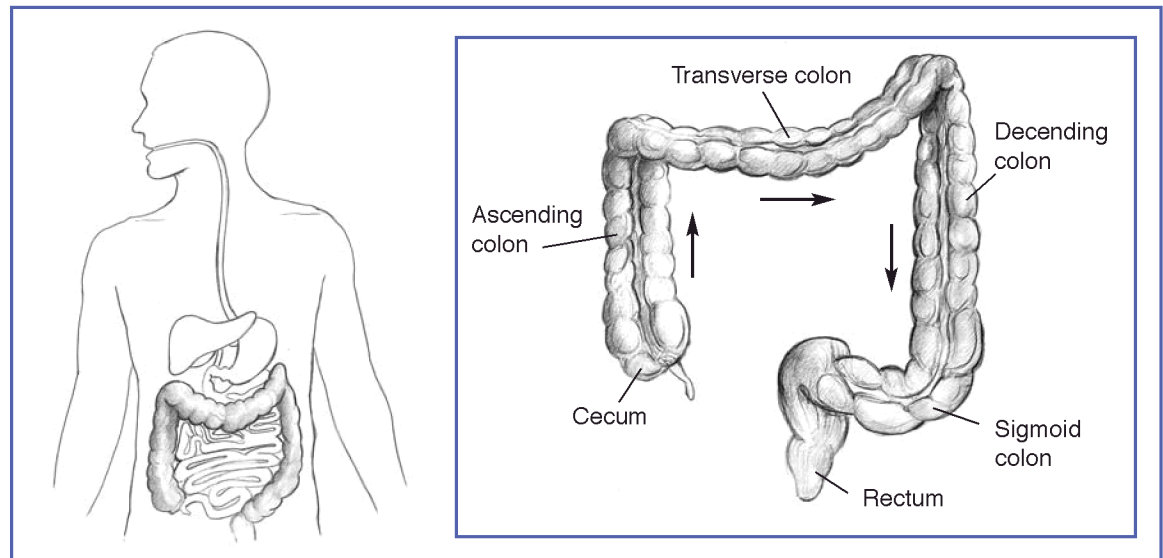
- Malrotation
- Small bowel and colonic intussusception
- Fistulas
- Colonic atresia
- Volvulus
- Imperforate anus

Colon Anatomy and Development

The adult colon is about 5 feet long. It connects to the small bowel, which is also known as the small intestine. The major functions of the colon are to absorb water and salts from partially digested food that enters from the small bowel and then send waste out of the body through the anus. What remains after absorption is stool, which passes from the colon into the rectum and out through the anus when a person has a bowel movement.

The colon comprises several segments:

- the cecum, the portion just after the small bowel
- the ascending colon
- the transverse colon
- the descending colon



Anatomic Problems of the Colon



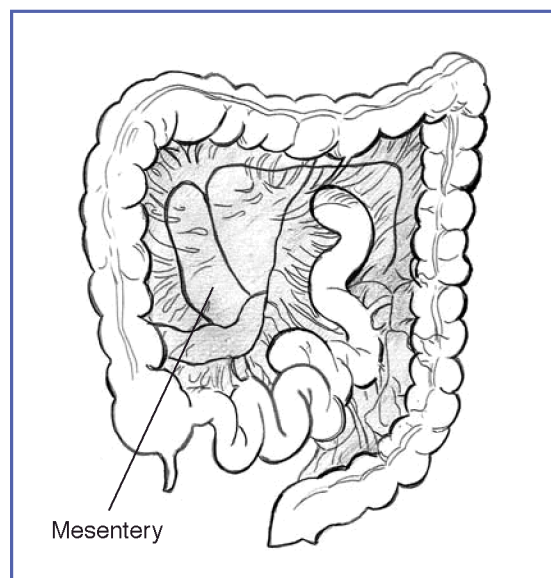
U.S. Department
of Health and
Human Services

- the sigmoid colon, an S-shaped portion near the end of the colon
- the rectum, where stool is stored until evacuation

The colon is formed during the first 3 months of embryonic development. As the bowel lengthens, part of it passes into the umbilical cord, which connects the fetus to the mother. As the fetus grows and the abdominal cavity enlarges, the bowel returns to the abdomen and turns, or rotates, counterclockwise to its final position. The small bowel and colon are held in position by tissue known as the mesentery. The ascending colon and descending colon are fixed in place in the abdominal cavity. The cecum, transverse colon, and sigmoid colon are suspended from the back of the abdominal wall by the mesentery.

Malrotation and Volvulus

If the bowel does not rotate completely during embryonic development, problems can occur. This condition is called malrota-



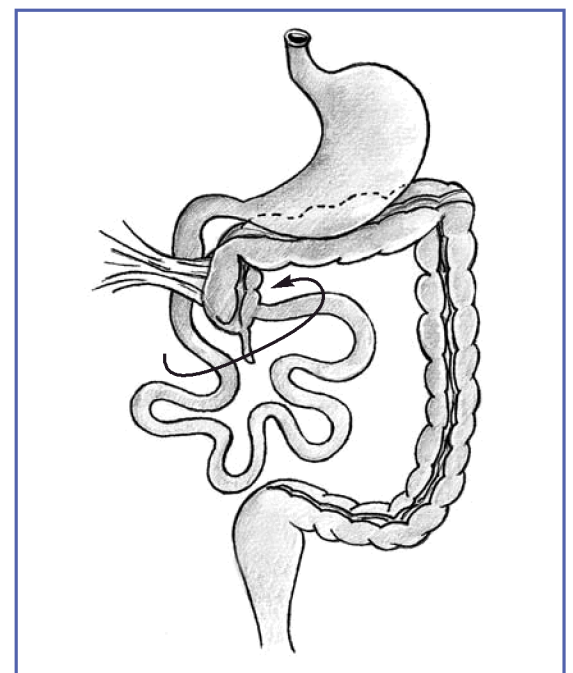
The colon is held in place by the mesentery.

tion. Normally, the cecum is located in the lower right part of the abdomen. If the cecum is not positioned correctly, the bands of thin tissue that normally hold it in place may cross over and block part of the small bowel.

Also, if the small bowel and colon have not rotated properly, the mesentery may be only narrowly attached to the back of the abdominal cavity. This narrow attachment can lead to a mobile or floppy bowel that is prone to twisting, a disorder called volvulus. (See the section on volvulus, page 5.)

Malrotation is also associated with other gastrointestinal (GI) conditions, including Hirschsprung's disease and bowel atresia.

Malrotation is usually identified in infants. About 60 percent of these cases are found in the first month of life. Malrotation affects both boys and girls, although boys are more often diagnosed in infancy.



In malrotation, the cecum is not positioned correctly. The tissue that normally holds it in place may cross over and block part of the small bowel.

In infants, the main symptom of malrotation is vomiting bile. Bile is a greenish-yellow digestive fluid made by the liver and stored in the gallbladder. Symptoms of malrotation with volvulus in older children include vomiting (but not necessarily vomiting bile), abdominal pain, diarrhea, constipation, bloody stools, rectal bleeding, or failure to thrive.

Various imaging studies are used to diagnose malrotation:

- **x rays to determine whether there is a blockage.** In malrotation, abdominal x rays commonly show that air, which normally passes through the entire digestive tract, has become trapped. The trapped air creates an enlarged, air-filled stomach and upper small bowel, with little or no air in the rest of the small bowel or the colon.
- **upper GI series to locate the point of intestinal obstruction.** With this test, the patient swallows barium to coat the stomach and small bowel before x rays are taken. Barium makes the organs visible on x ray and indicates the point of the obstruction. This test cannot be done if the patient is vomiting.
- **lower GI series to determine the position of the colon.** For this test, a barium enema is given while x rays are taken. The barium makes the colon visible so the position of the cecum can be determined.
- **computed tomography (CT) scan to help determine and locate the intestinal obstruction.**

Malrotation in infants is a medical emergency that usually requires immediate surgery. Surgery may involve

- untwisting the colon
- dividing the bands of tissue that obstruct the small bowel

- repositioning the small bowel and colon
- removing the appendix

Surgery to relieve the blockage of the small bowel is usually successful and allows the digestive system to function normally.

Small Bowel and Colonic Intussusception

Intussusception is a condition in which one section of the bowel tunnels into an adjoining section, like a collapsible telescope. Intussusception can occur in the colon, the small bowel, or between the small bowel and colon. The result is a blocked small bowel or colon.

Intussusception is rare in adults. Causes include

- benign or malignant growths
- adhesions (scarlike tissue)
- surgical scars in the small bowel or colon
- motility disorders (problems with the movement of food through the digestive tract)
- long-term diarrhea

Some cases of intussusception have been associated with viral infections and in patients living with AIDS. It can also occur without any known cause (idiopathic).

In infants and children, intussusception involving the small bowel alone, or the small bowel and the colon, is one of the most common causes of intestinal obstruction. Malrotation is a risk factor. Intussusception affects boys more often than girls, with most cases happening at 5 months and at 3 years of age. Most cases in children have no known cause, but viral infections or a growth in the small bowel or colon may trigger the condition. In the past, cases of intussusception appeared to be associated

with a childhood vaccine for rotavirus, a common cause of gastroenteritis (intestinal infection). That vaccine is no longer given.

In adults with intussusception, symptoms can last a long time (chronic symptoms) or they can come and go (intermittent symptoms). The symptoms will depend on the location of the intussusception. They may include

- changes in bowel habits
- urgency—needing to have a bowel movement immediately
- rectal bleeding
- chronic or intermittent crampy abdominal pain
- pain in a specific area of the abdomen
- abdominal distention
- nausea and vomiting

Children with intussusception may experience

- intermittent abdominal pain
- bowel movements that are mixed with blood and mucus
- abdominal distention or a lump in the abdomen
- vomiting bile
- diarrhea
- fever
- dehydration
- lethargy
- shock (low blood pressure, increased heart rate requiring immediate attention)

If intussusception is not diagnosed promptly, especially in children, it can cause serious damage to the portion of the bowel that is unable to get its normal blood supply. A range of diagnostic tests may be required. X rays of the abdomen may suggest a bowel obstruction (blockage). Upper and lower GI series will locate the intussusception

and show the telescoping. CT scans can also help with the diagnosis. When intussusception is suspected, an air or barium enema can often help correct the problem by pushing the telescoped section of bowel into its proper position.

Both adults and children may require surgery to straighten or remove the involved section of bowel. The outcome of this surgery depends on the stage of the intussusception at diagnosis and the underlying cause. With early treatment, the outcome is generally excellent. In some cases, usually in children, intussusception may be temporary and reverse on its own. If no underlying cause is found in these cases, no specific treatment is required.

Fistulas

A fistula is an abnormal passageway between two areas of the digestive tract. An internal fistula occurs between two areas of intestine or an area of intestine and another organ. An external fistula occurs between the intestine and the outside of the body. Both internal and external fistulas may be characterized by abdominal pain and swelling. External fistulas may discharge pus or intestinal contents. Internal fistulas can be associated with diarrhea.

The most common types of fistulas develop around the anus, colon, and small bowel. These types are

- ileosigmoid—occurs between the sigmoid colon and the end of the small bowel, which is also called the ileum
- ileocecal—occurs between the ileum and cecum
- anorectal—occurs between the anal canal and the skin around the anus
- anovaginal—occurs between the rectum and vagina

- colovesical—occurs between the colon and bladder
- cutaneous—occurs between the colon or small bowel and the outside of the body

Fistulas can occur at any age. Some fistulas are congenital, which means they occur during the development of a baby. They are seen in infants and are more common in boys. Other fistulas develop suddenly due to diseases or after trauma, surgery, or local infection. A fistula can form when diseased or damaged tissue comes into contact with other damaged or nondamaged tissue, as seen in Crohn's disease (intestinal inflammation) and diverticulitis. Childbirth can lead to fistulas between the rectum and vagina in women.

External fistulas are found during a physical examination. Internal fistulas can be seen by colonoscopy, upper and lower GI series, or CT scan.

Fistulas may be treated by surgery to remove the portion of the intestine causing the fistula, along with antibiotics to treat any associated infection.

Colonic Atresia

Colonic atresia is a condition that occurs during embryonic development in which the normal tubular shape of the colon in the fetus is unexpectedly closed. This congenital abnormality may be caused by incomplete development of the colon or the loss of blood flow during its development. Colonic atresia is rare and may occur with the more common small bowel atresia.

Infants with colonic atresia have no bowel movements, increasing abdominal distention, and vomiting. X rays will show a dilated colon above the obstruction, which can then be located using a barium enema.

Surgery is necessary to open or remove the closed area and re-connect the normal sections of the colon.

Volvulus

Volvulus refers to the twisting of a portion of the intestine around itself or a stalk of mesentery tissue to cause an obstruction. Volvulus occurs most frequently in the colon, although the stomach and small bowel can also twist. The part of the digestive system above the volvulus continues to function and may swell as it fills with digested food, fluid, and gas. A condition called strangulation develops if the mesentery of the bowel is twisted so tightly that blood flow is cut off and the tissue dies. This condition is called gangrene. Volvulus is a surgical emergency because gangrene can develop quickly, cause a hole in the wall of the bowel (perforation), and become life-threatening.

In the colon, volvulus most often involves the cecum and sigmoid segment. Sigmoid volvulus is more common than cecal volvulus.

Sigmoid Volvulus

The sigmoid is the last section of the colon. Two anatomic differences can increase the risk of sigmoid volvulus. One is an elongated or movable sigmoid colon that is unattached to the left sidewall of the abdomen. Another is a narrow mesentery that allows twisting at its base. Sigmoid volvulus, however, can occur even without an anatomic abnormality.

Risk factors that can make a person more likely to have sigmoid volvulus are Hirschsprung's disease, intestinal pseudo-obstructions, and megacolon (an enlarged colon). Adults, children, and infants can all have sigmoid volvulus. It is more common in men than in women, possibly because

men have longer sigmoid colons. It is also more common in people over age 60, in African Americans, and in institutionalized individuals who are on medications for psychiatric disorders. In addition, children with malrotation are more likely to get sigmoid volvulus.

The symptoms can be acute (occur suddenly) and severe. They include a bowel obstruction (commonly seen in infants), nausea, vomiting, bloody stools, abdominal pain, constipation, and shock. Other symptoms can develop more slowly but increase over time, such as severe constipation, lack of passing gas, crampy abdominal pain, and abdominal distention. A doctor may also hear increased or decreased bowel sounds.

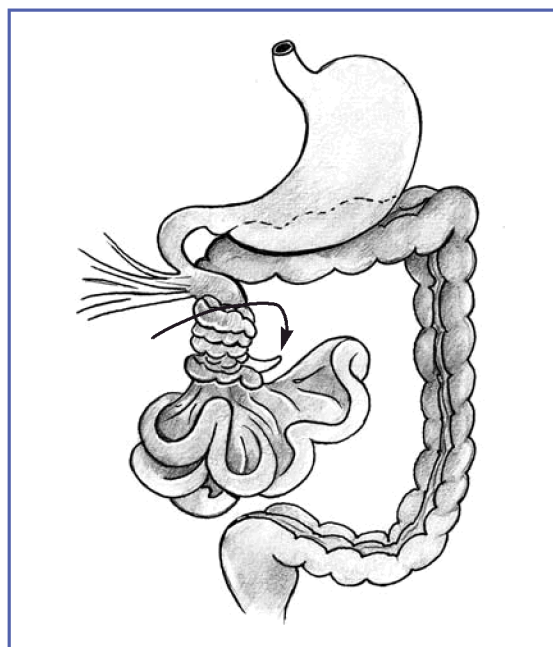
Several tests are used to diagnose sigmoid volvulus. X rays show a dilated colon above the volvulus. Upper and lower GI series help locate the point of obstruction and show whether malrotation of the rest of the colon is present. A CT scan may be used to show the degree of twisting and malrotation, and whether perforation has occurred.

In most instances, a sigmoidoscope, a tube used to look into the sigmoid colon and rectum, can be used to reach the site, untwist the colon, and release the obstruction. However, if the colon is found to be twisted very tightly or is twisted so tightly that blood flow is cut off and the tissue is dead, immediate surgery will be needed to correct the problem and, if possible, restore the blood supply. Dead tissue will be removed during surgery, and a portion of the colon may be removed as well—a procedure called a resection. Sigmoid volvulus can recur after untwisting with the sigmoidoscope, but resection eliminates the chance of recurrence. Prompt diagnosis of sigmoid volvulus and appropriate treatment generally lead to a good outcome.

Cecal Volvulus

Cecal volvulus is the twisting of the cecum and ascending segment of the colon. Normally, the cecum and ascending colon are fixed to the internal abdominal wall. If not, they can move and become twisted. The main symptoms of cecal volvulus are crampy abdominal pain and swelling that are sometimes associated with nausea and vomiting.

In testing, x rays will show the cecum out of its normal place and inflated with trapped air. The appendix may be filled with gas, but little or no gas is seen in other parts of the colon. Upper and lower GI series will locate the volvulus and the position of the colon. A CT scan may show how tightly the volvulus is twisted. A colonoscopy, which uses a small, flexible tube with a light and a lens on the end to see the inside of the colon, can sometimes be used to untwist the volvulus. If the cecum becomes gangrenous or holes develop in it, surgery will be needed.



In volvulus, a portion of the intestine twists around itself.

Imperforate Anus (Anal Atresia)

Imperforate anus or anal atresia is a congenital abnormality in which the anorectal region is abnormal or incompletely developed. In some cases, the rectum may end and not connect with the anus, or it may connect in the wrong spot. For example, it may connect to the urethra, bladder, or vagina. (See the section on fistulas, page 4). In other cases, the anus may be very narrow or missing altogether. The result is that stool cannot pass out of the colon. Imperforate anus occurs in about 1 in 5,000 infants.

Another malformation that results in absence of a functioning anus is congenital cloaca. In patients with this abnormality, the anal muscles and vagina fail to form and the result is a large, ill-defined opening that represents the rectum as well as the vagina and bladder, depending on the extent of the defect. Cloaca deformity of the anus usually requires a colostomy but may be correctable with a surgical procedure that transfers a muscle from another part of the body to create a functioning sphincter at the anus.

Symptoms of imperforate anus include

- no bowel movement within 24 to 48 hours after birth
- a missing or misplaced anal opening
- stool that comes out of the vagina or urethra
- abdominal swelling (distention)

Imperforate anus is usually found when the infant is first examined after birth. Imperforate anus is categorized on the basis of the location of the end of the rectum in relation to the muscles that support the rectum and other organs in the pelvis,

called the levator ani muscles. These location categories are

- high: the rectum ends above the muscles
- intermediate: the rectum ends at the level of the muscles
- low: the rectum ends below the muscles

In all cases of imperforate anus, surgery is necessary to reconstruct the anus. Low imperforate anus is corrected through a minor procedure just after birth. High imperforate anus may require surgery to separate the rectum from the other organs if the rectum is connected with them. The outcome is usually very good, but some infants may not develop good bowel control after surgery because the anal muscles may not form. A child with high imperforate anus often has other GI problems, such as malrotation and intestinal atresia.

Factors that affect the outcome of treatment include the location of the abnormality, the patient's sex, and the age at which the surgery is done. Surgery to correct low imperforate anus in boys usually has an excellent outcome. Correcting cloaca in girls requires a more difficult procedure and is more prone to complications.

Hope Through Research

The National Institute of Diabetes and Digestive and Kidney Diseases, through its Division of Digestive Diseases and Nutrition, supports basic and clinical research into GI diseases, including GI structure; the growth of GI cells in normal and disease states; tissue injury, repair, and regeneration; and Crohn's disease. Research includes new methods that will help physicians and researchers see inside the body, thereby increasing the detection rate for anatomic problems of the colon.

Points to Remember

- Anatomic problems of the colon are caused by changes in the shape of the colon or the way it connects to other organs.
- Anatomic problems may be congenital or develop with age.
- Anatomic problems can block the passage of food through the digestive system. Some problems can become life-threatening.
- Symptoms of anatomic problems include abdominal pain, abdominal distension, vomiting, and diarrhea or constipation.
- Some anatomic problems may resolve over time; others may need to be corrected with surgery.

For More Information

Crohn's & Colitis Foundation of America (CCFA)

386 Park Avenue South, 17th Floor
New York, NY 10016-8804
Phone: 1-800-932-2423 or 212-685-3440
Fax: 212-779-4098
Email: info@ccfa.org
Internet: www.ccfa.org

International Foundation for Functional Gastrointestinal Disorders (IFFGD)

P.O. Box 170864
Milwaukee, WI 53217-8076
Phone: 1-888-964-2001 or 414-964-1799
Fax: 414-964-7176
Email: iffgd@iffgd.org
Internet: www.iffgd.org

National Digestive Diseases Information Clearinghouse

2 Information Way
Bethesda, MD 20892-3570
Phone: 1-800-891-5389
Fax: 703-738-4929
Email: nddic@info.niddk.nih.gov
Internet: www.digestive.niddk.nih.gov

The National Digestive Diseases Information Clearinghouse (NDDIC) is a service of the National Institute of Diabetes and Digestive and Kidney Diseases (NIDDK). The NIDDK is part of the National Institutes of Health under the U.S. Department of Health and Human Services. Established in 1980, the clearinghouse provides information about digestive diseases to people with digestive disorders and to their families, health care professionals, and the public. NDDIC answers inquiries, develops and distributes publications, and works closely with professional and patient organizations and Government agencies to coordinate resources about digestive diseases.

Publications produced by the clearinghouse are carefully reviewed by both NIDDK scientists and outside experts. This fact sheet was reviewed by Robert Beart, M.D., University of Southern California; James W. Fleshman, M.D., Washington University and Barnes-Jewish Hospital; Kevan Jacobson, M.B.B.Ch, B.C.'s [British Columbia, Canada's] Children's Hospital; Joseph Levy, M.D., Children's Hospital of New York-Presbyterian; and John H. Pemberton, M.D., Mayo Clinic.

This publication is not copyrighted. The clearinghouse encourages users of this fact sheet to duplicate and distribute as many copies as desired.

This fact sheet is also available at www.digestive.niddk.nih.gov.



U.S. DEPARTMENT OF HEALTH
AND HUMAN SERVICES
National Institutes of Health

NIH Publication No. 05-5120
February 2005